



THE UNIVERSITY OF  
TENNESSEE  
HEALTH SCIENCE CENTER.

# Surgical Management of Portal Hypertension

RYAN A. HELMICK, MD

UNIVERSITY OF TENNESSEE HEALTH SCIENCE CENTER  
METHODIST TRANSPLANT INSTITUTE, MEMPHIS, TENNESSEE

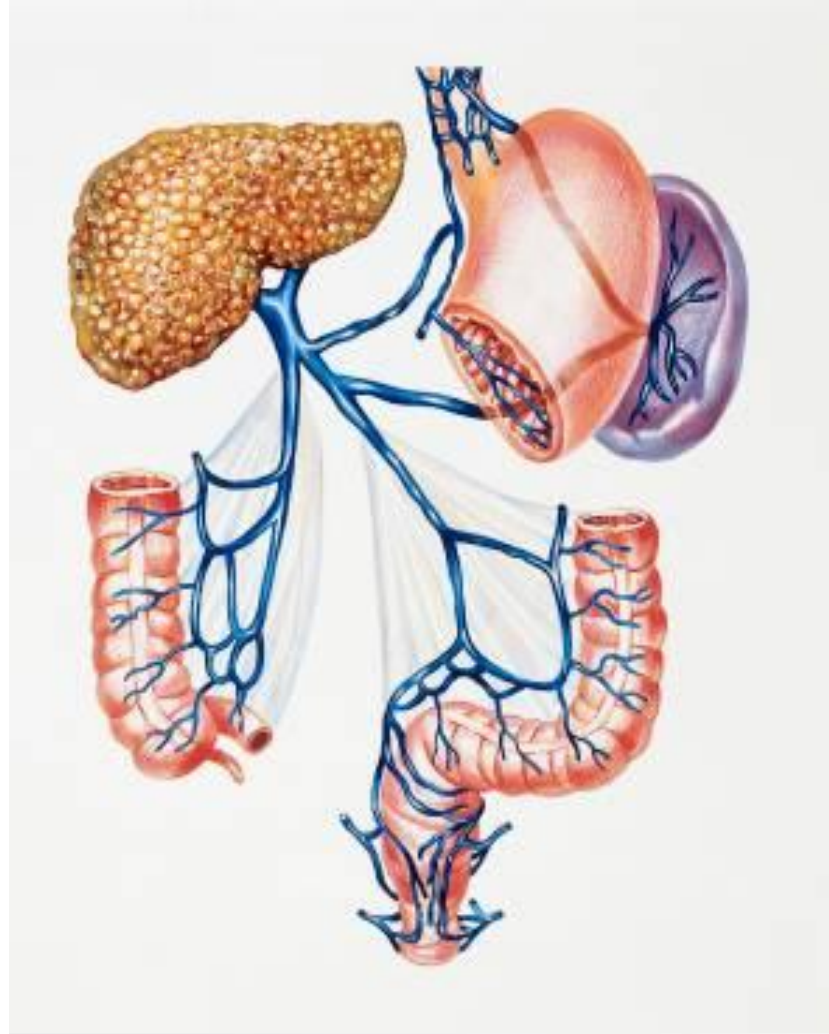# Disclosures

- I have no financial disclosures related to this topic.
- I also have no first-hand experience with surgical operations for management of portal hypertension.
- Most figures courtesy of *Blumgart's Surgery of the Liver, Biliary Tract and Pancreas*

# Objectives

- To review the surgical options available to surgeons for the management of portal hypertension
- To discuss the rates of utilization of surgical options for portal hypertension versus radiologic treatment modalities
- To weigh the pros and cons for the above options, and the factors involved in choosing a modality depending on patient factors

# Portal Venous System



# Why is this important?

- Portal hypertension = late-stage finding
- Symptoms -> mortality risk
  - Ascites – median survival 1.08 years
  - Hepatic encephalopathy – median survival 0.95 years for those aged 65+
  - Spontaneous Bacterial Peritonitis – median survival 11 weeks
  - Variceal bleeding – 17.7% 6-week mortality after variceal bleed

Tapper EB, Parikh ND. Diagnosis and Management of Cirrhosis and Its Complications: A Review. JAMA 2023; 329: 1589.

# Goal #1



# Treatment for Bleeding Varices

- Medical therapies
  - $\beta$ -blockers
  - Octreotide
  - Antibiotics
    - Gram-negative rods, oral gram-positive organisms

# Balloon Tamponade ~ 1950s






# A Crazy Idea Takes Hold...



What about...  
ligating those  
bleeders?



# Variceal ligation

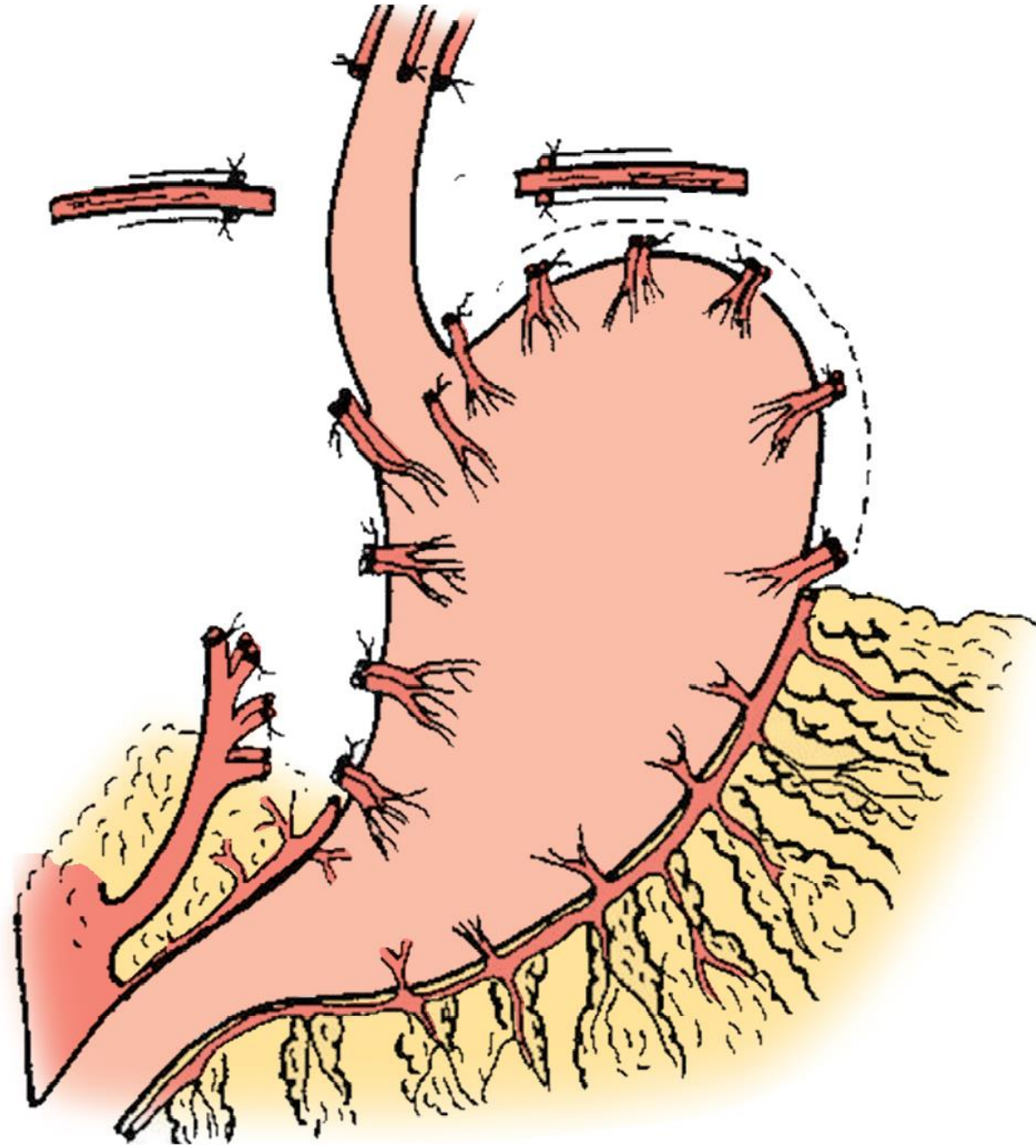
- 1950 – Boerema and Crile > ligation of esophageal varices
- 1964 – Walker > transthoracic esophageal transection
- 1950s – 6 reports on gastroesophageal resection
- 50s/60s - 3 reports on upper gastric resection
- Transabdominal esophageal resection

Unsatisfactory  
Outcomes

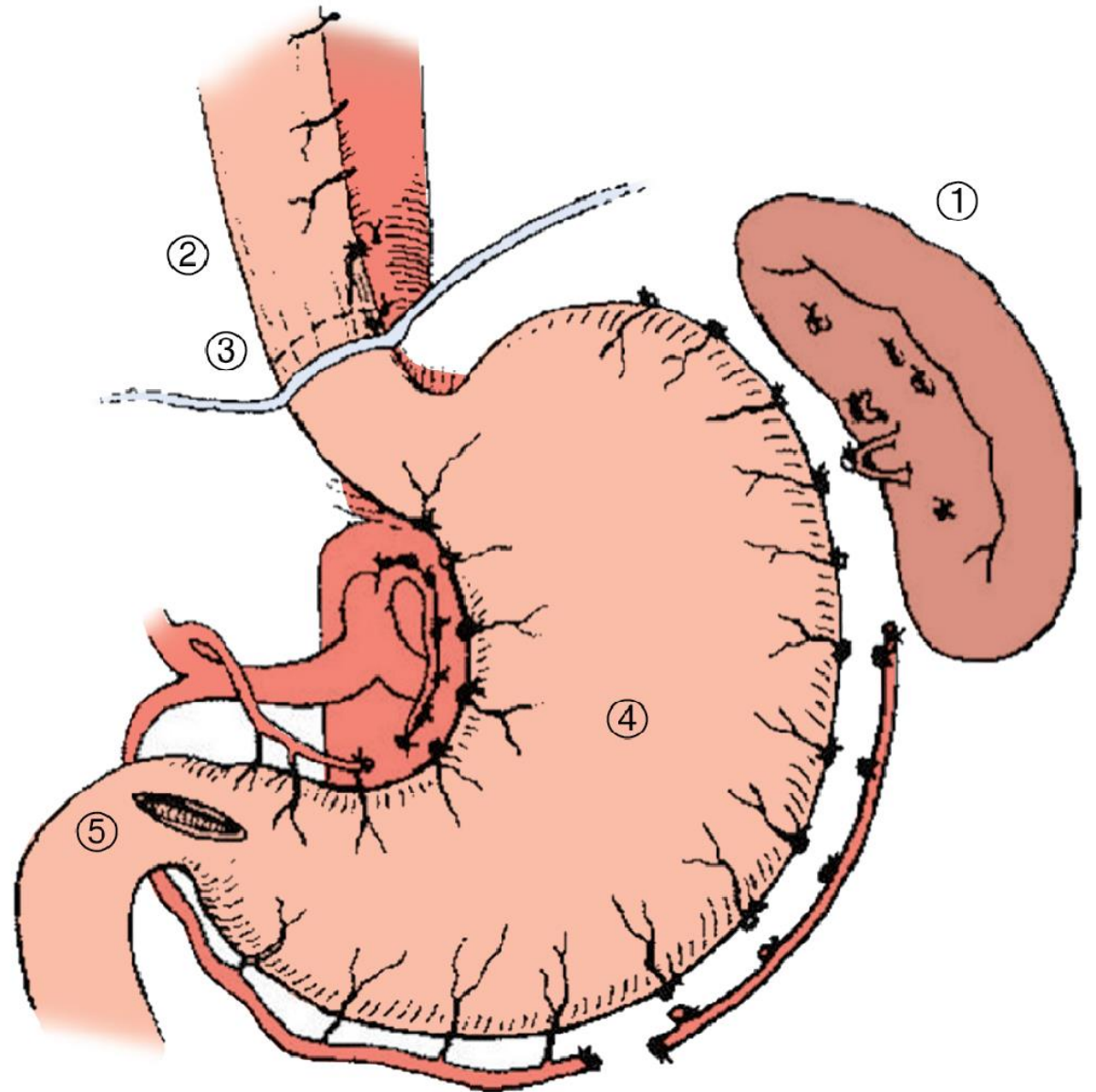
# Devascularization Progress

- 1957 – Mohammed Aboul-Fotouh Hassab at Cairo University
  - Devised a devascularization with splenectomy procedure
  - Reported 355 cases by 1967
    - Initial indications were Schistosomiasal portal hypertension
- 1967 – Mitsuo Sugiura and Shunji Futagawa
  - Added transthoracic esophageal transection to devascularization and splenectomy
  - Reported 276 cases in 1977

# Hassab



# Sugiura-Futugawa



# Hassab and Sugiura Results

- Hassab
  - Complications – gastric outlet obstruction
  - Rebleeding rates – 6-8%
  - 5-year survival – 73-85% \*
- Sugiura
  - Complications – esophageal leakage
  - Rebleeding rates – 1.5-16%
  - 5-year survival - ~70%, 30% when emergent
- RCT - Endoscopic ligation, Hassab, and Hassab plus endoscopy
  - 83% variceal recurrence, 95% variceal recurrence with 30% re-bleed, and 8% recurrence, respectively
- RCT - Pharmacology vs. Sclerotherapy vs. Sugiura-Futugawa operation
  - Rebleeding rate 68%, 71% and 5% respectively for Child A cirrhotics

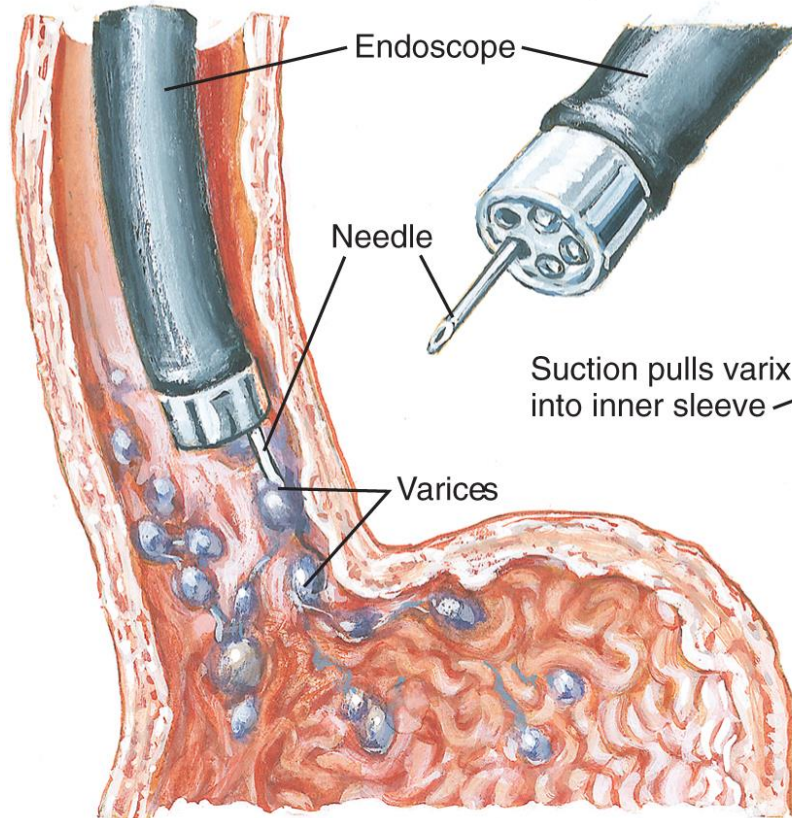


# When to Devascularize?

- Patients with bleeding esophageal varices
- Non-cirrhotic portal hypertension or Child's A/B cirrhosis
- No shunt options
- Not a transplant candidate

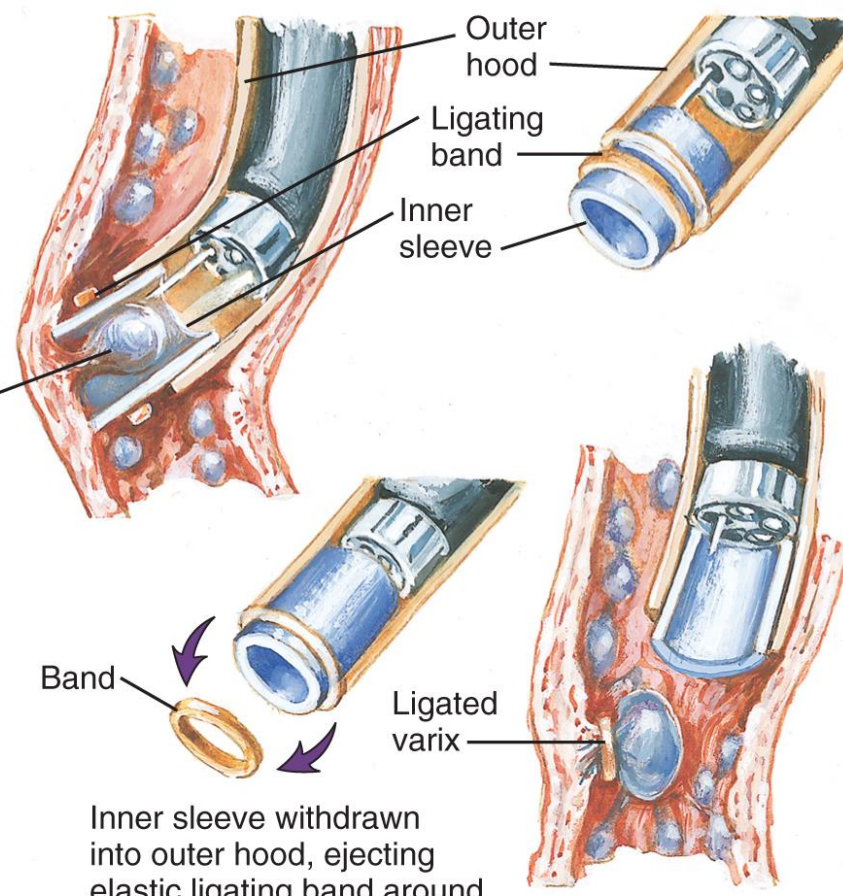
# An Aside to Mention Endoscopy ~ 1970s

## Endoscopic variceal sclerotherapy



Needle passed through standard endoscope into varix. Injected sclerosing solution causes thrombosis of varix

## Endoscopic variceal ligation (banding)



Inner sleeve withdrawn into outer hood, ejecting elastic ligating band around base of varix

JOHN A. CRAIG MD



# Surgical Portosystemic Shunts

## **Non-selective shunts**

- All portal flow diverted to systemic circulation

## **Selective shunts**

- Preserves some portal flow to the liver while decompressing the portal circulation

# Surgical Portosystemic Shunts

## Non-selective shunts

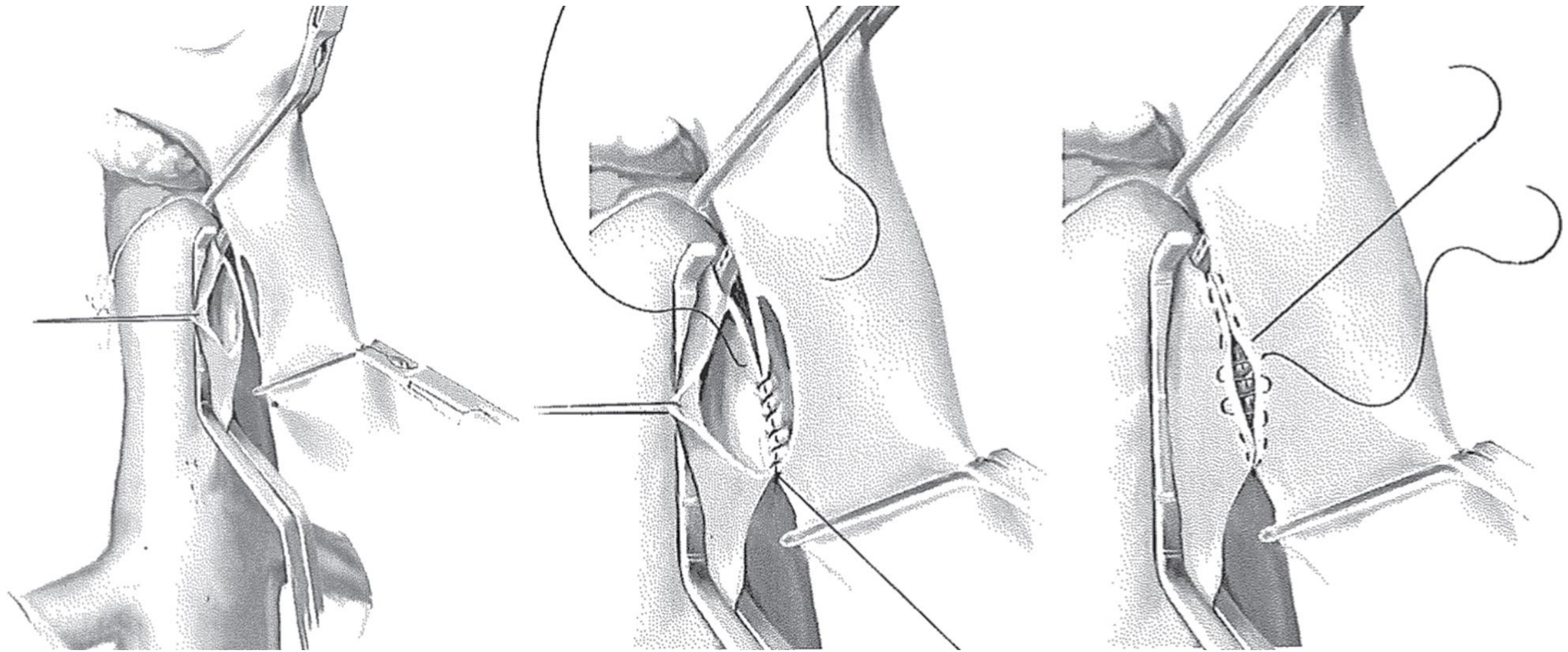
- Portocaval shunts
- Central Splenorenal Shunts
- Large diameter 16mm H-graft shunt
  - Portocaval
  - Mesocaval

## Selective shunts

- Distal Splenorenal Shunts
- Small Diameter 8mm H-graft shunt
  - Portocaval
  - Mesocaval

# Portacaval Shunt

- Direct connection between portal vein and cava
  - End to side
  - Side to side
    - Removal of a patch of IVC and PV help to ensure a wide anastomosis
  - Interposition grafting
- Effective portal system decompression – a gradient  $> 4-5$ mmHg indicates a technical issue



# Portacaval Shunt (cont.)

- Comparison between emergent endoscopic sclerotherapy and direct portocaval shunting
  - Bleeding prevention successful in 20% of the EST group vs. 100% of the PCS group
  - Higher overall survival in the PCS group
  - 50% of the EST group required rescue shunting
- Shortcomings
  - Encephalopathy
  - Makes OLT a re-operative procedure

# Mesocaval Shunt

- Anastomosis between the SMV and IVC
- Size of graft -> selective or non-selective
  - Depends functionally on the amount of residual flow to liver
- Two potential configurations
  - H-graft - short segment graft from posterior of SMV to the IVC
  - C-graft - longer segment graft from anterior, more proximal SMV to the IVC



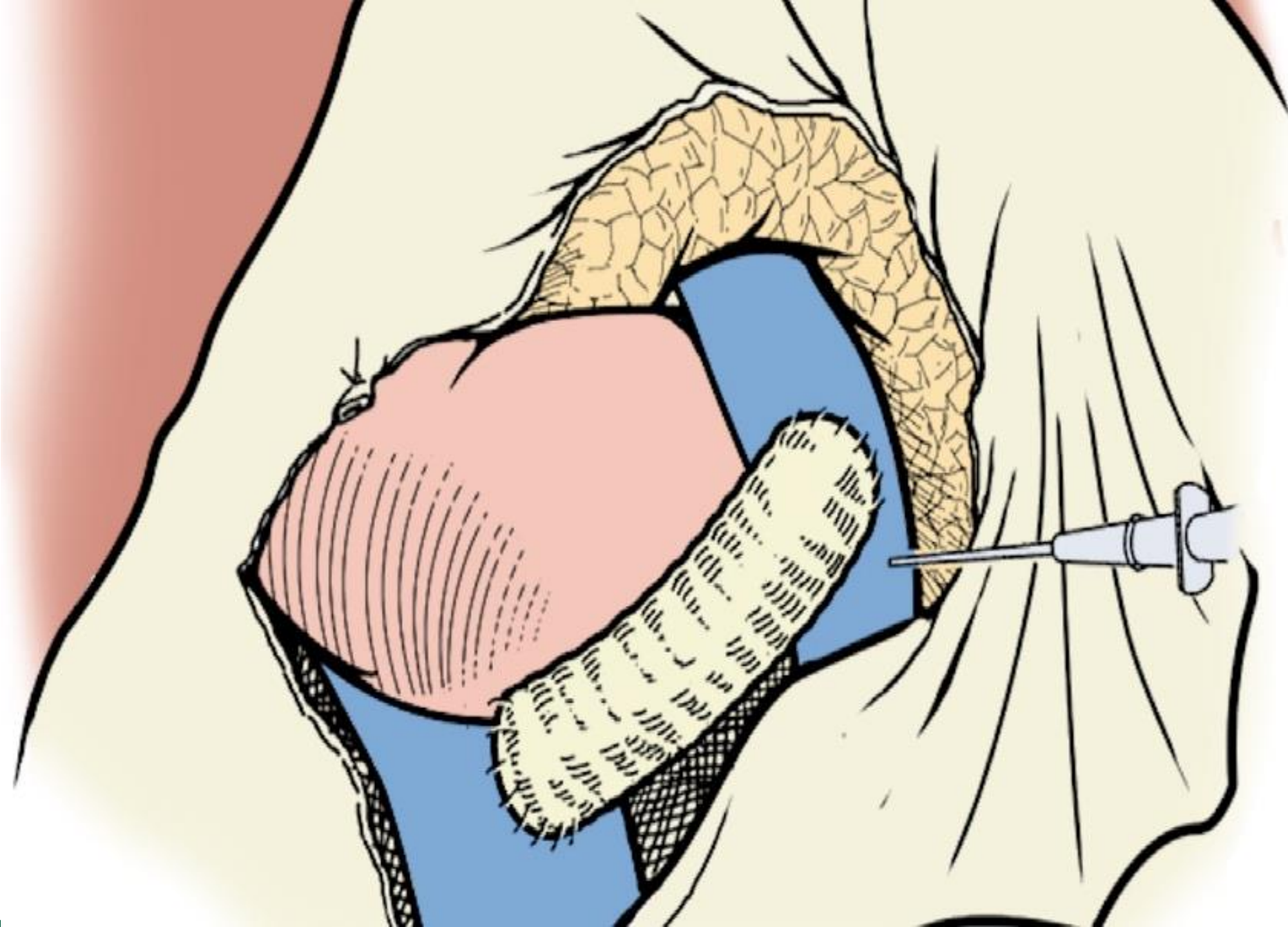
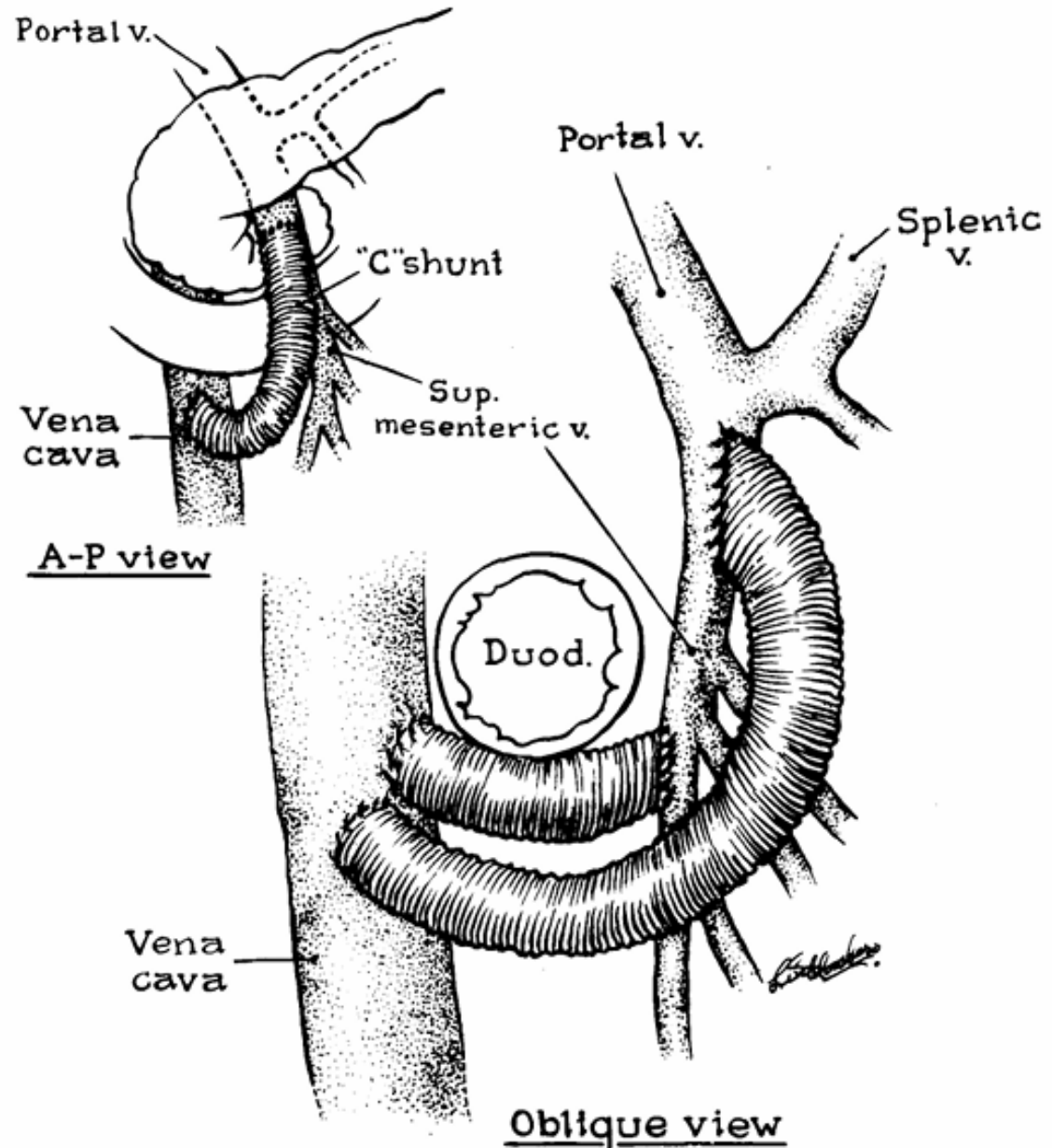


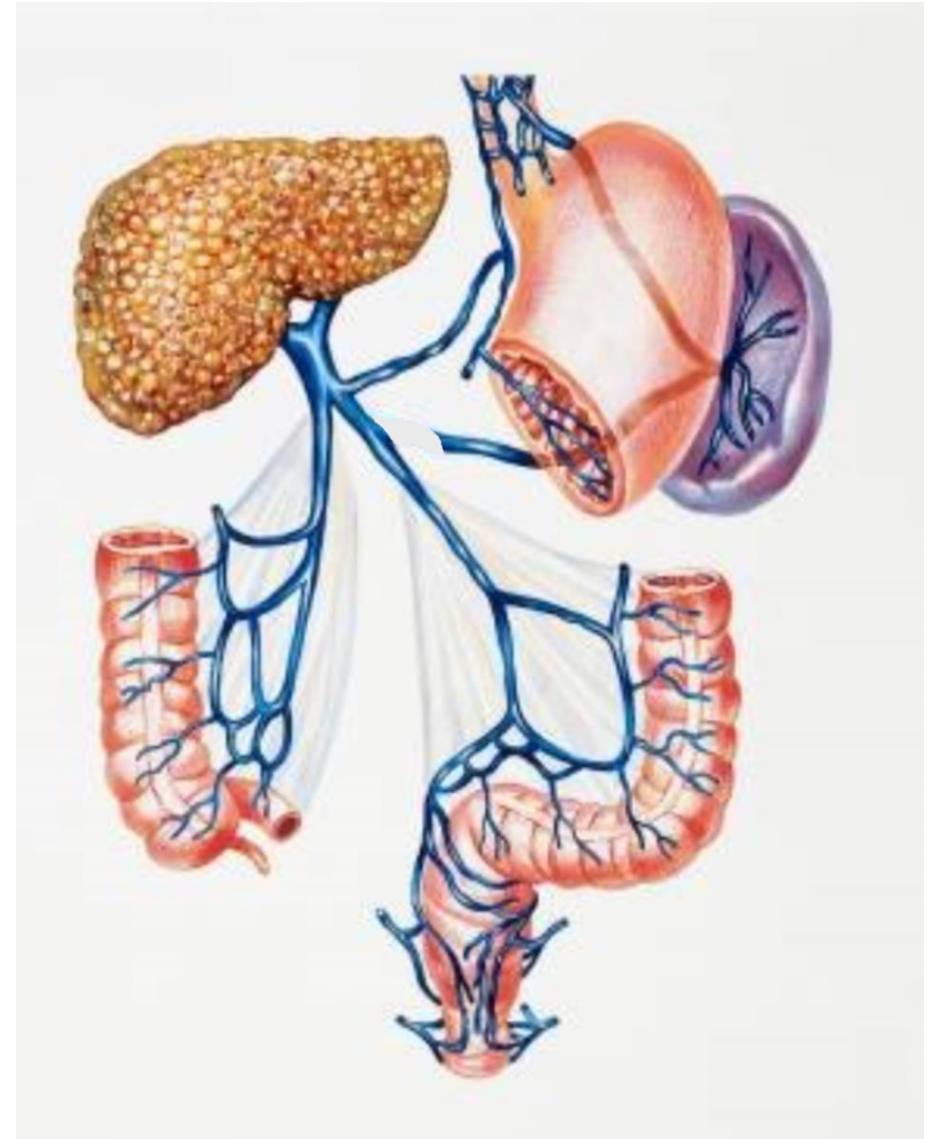
Figure 1. Relative positions of the interposed prosthesis with the mesocaval H-shunt and the mesocaval C-shunt. The C-shunt is anastomosed to the anterior surface of the superior mesenteric vein just before it joins the splenic vein and above all of its branches. The H-shunt is anastomosed to the posterior surface of the superior mesenteric vein at the level of the duodenum and frequently at the site of branching. (From Cameron JL, Harrington DP, Maddrey WC: The mesocaval C-shunt. *Surg Gynecol Obstet* 150:401, 1980; by permission of Surgery, Gynecology & Obstetrics.)





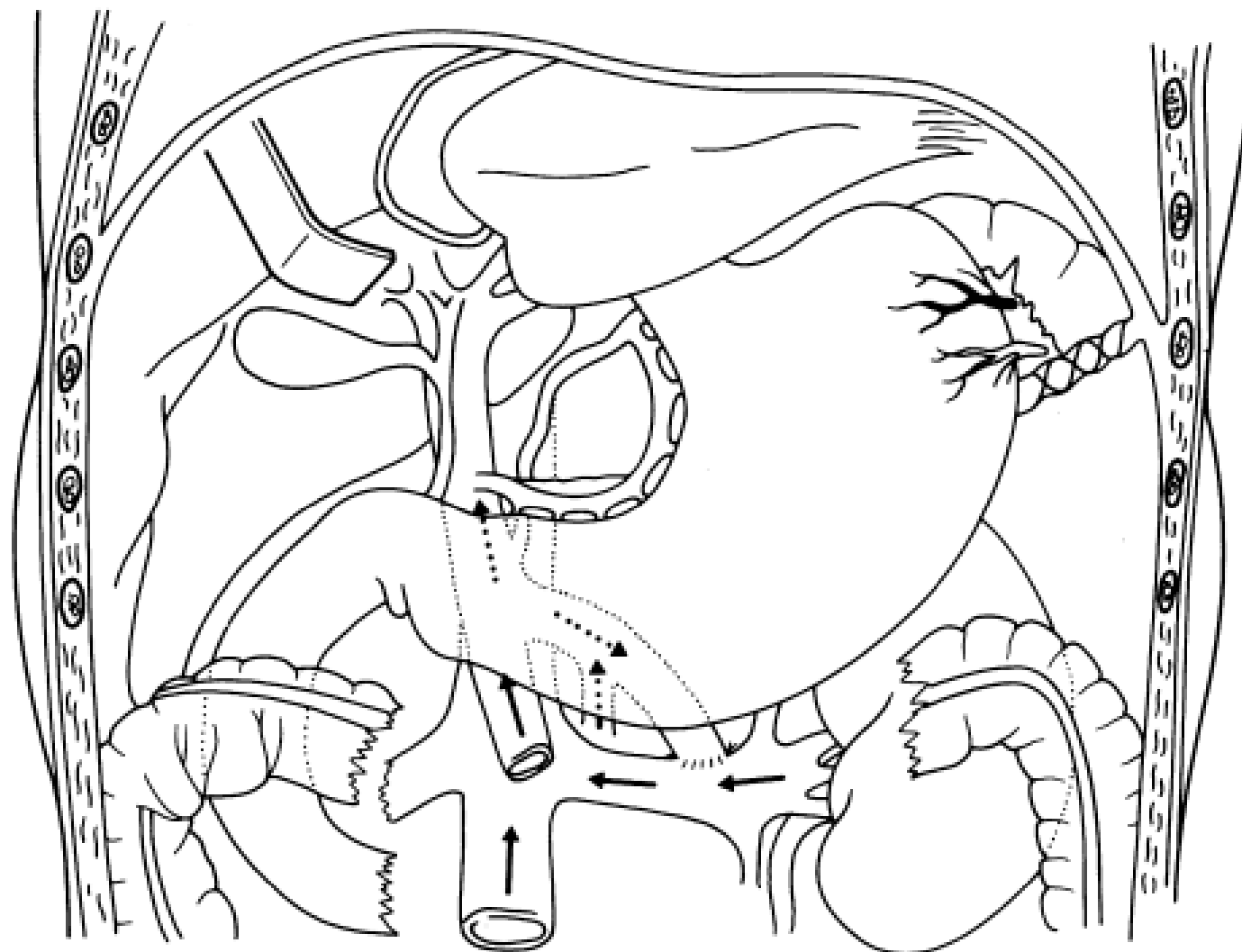
# Mesocaval Shunt (cont.)

- Advantages – avoids portal dissection, making eventual transplant easier
- Disadvantages
  - Graft thrombosis can lead to SMV and portal clot propagation
  - Will not decompress gastric varices if there is splenic vein thrombosis
  - Reports of erosion into the duodenum



# Central Splenorenal Shunts

- Non-selective shunt
- Involves partial splenectomy, division of splenic vein
- End to side splenorenal anastamosis



**Figure 2** Sketch of the surgery showing the subtotal splenectomy and the splenorenal anastomosis.

# Distal Splenorenal Shunt

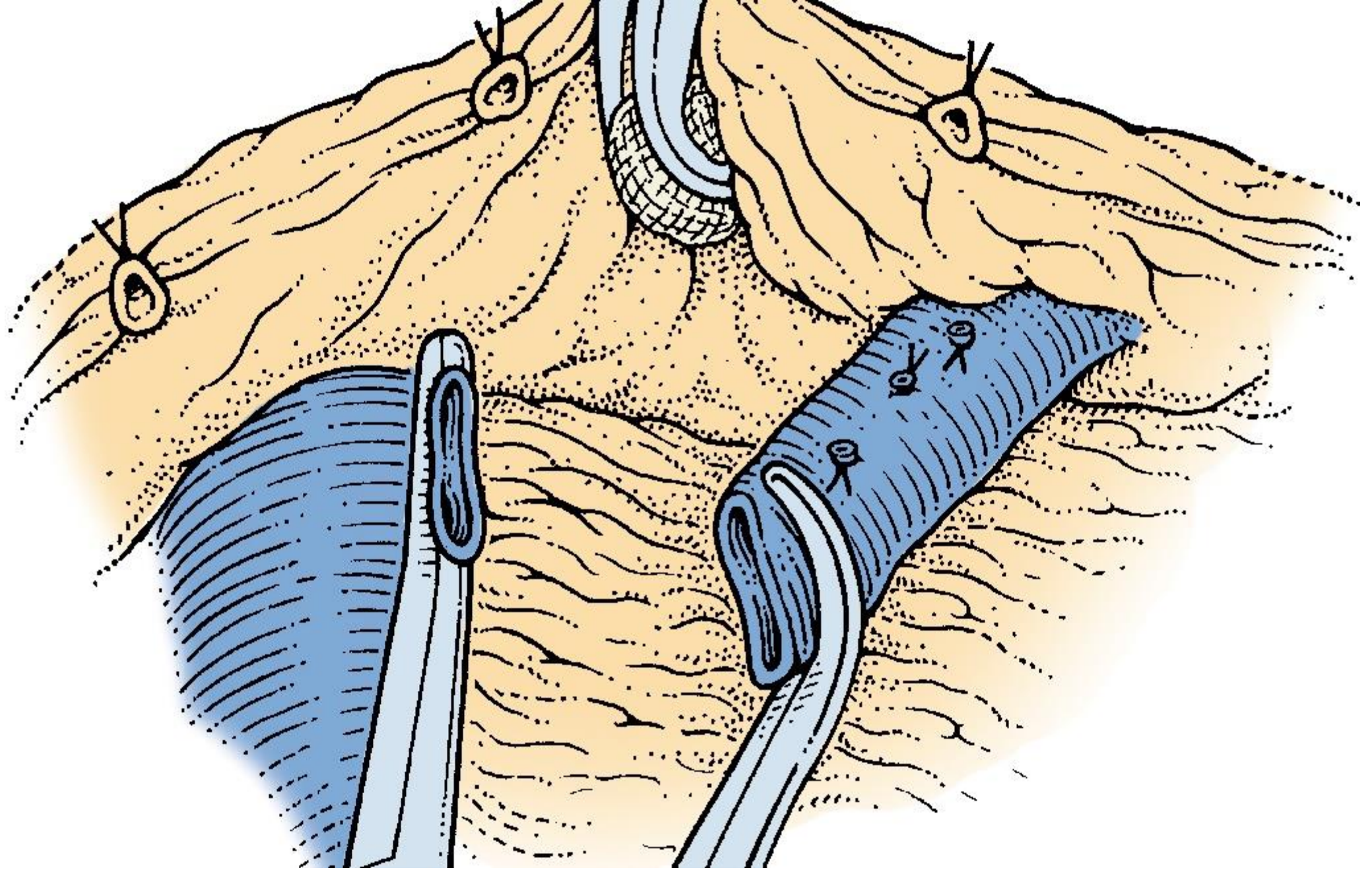
- Warren or Warren-Zeppa Shunt



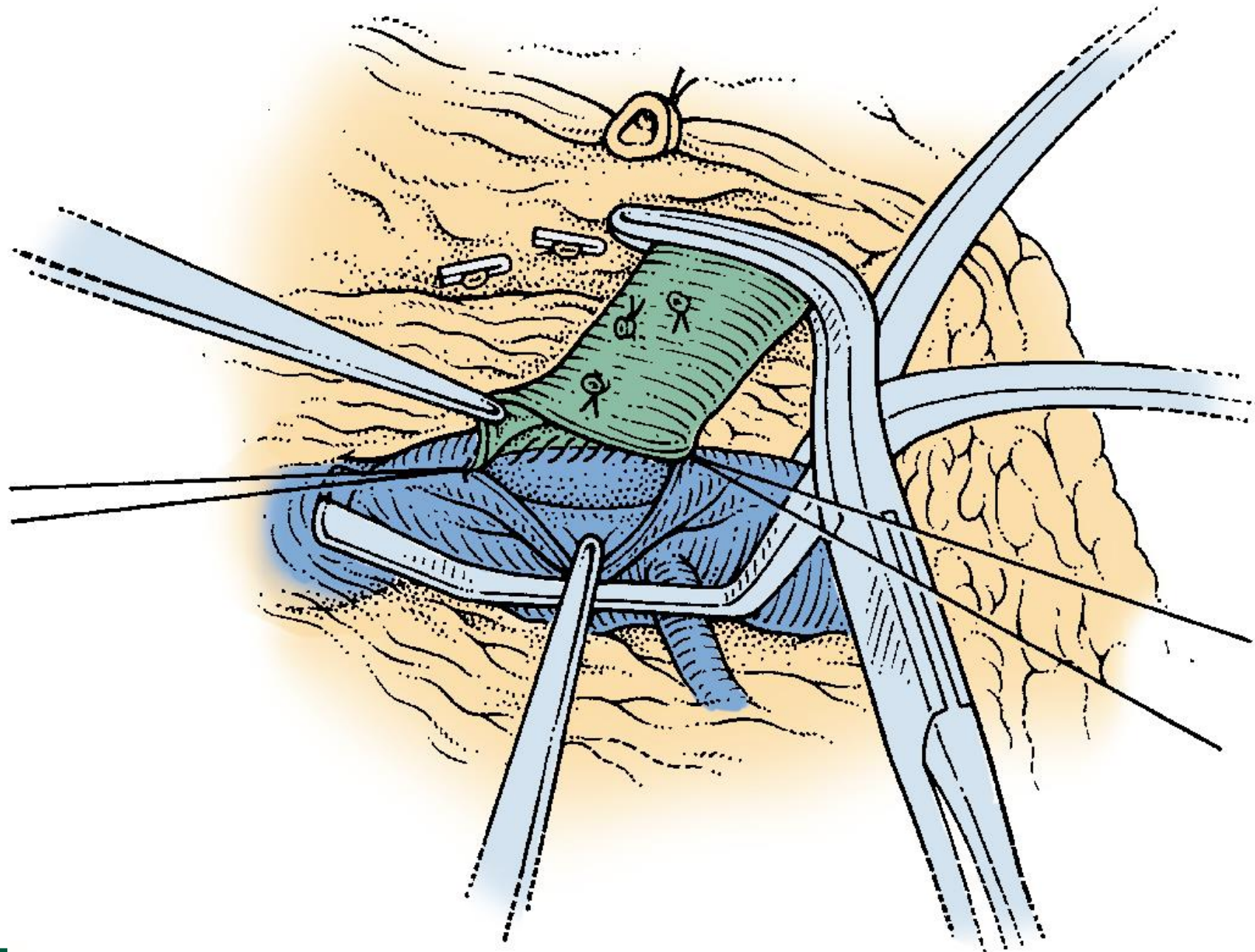
# Distal Splenorenal Shunt (cont.)

- Conceptually separates the spleen, gastroesophageal varices from the SMV/PV
- Preserves more flow through liver
- Lowers pressure in PV less than more central shunts
- Unable to follow for more active surveillance
- Lower rates of re-bleeding compared to endoscopy
  - Similar rates to other shunts and TIPS









# Distal Splenorenal Shunt (cont.)

- Increased encephalopathy vs. endoscopy
  - Early reports suggest DSRS have lower encephalopathy rates compared to non-selective shunts
- DSRS occlusion/dysfunction rate was 7.8% over four trials

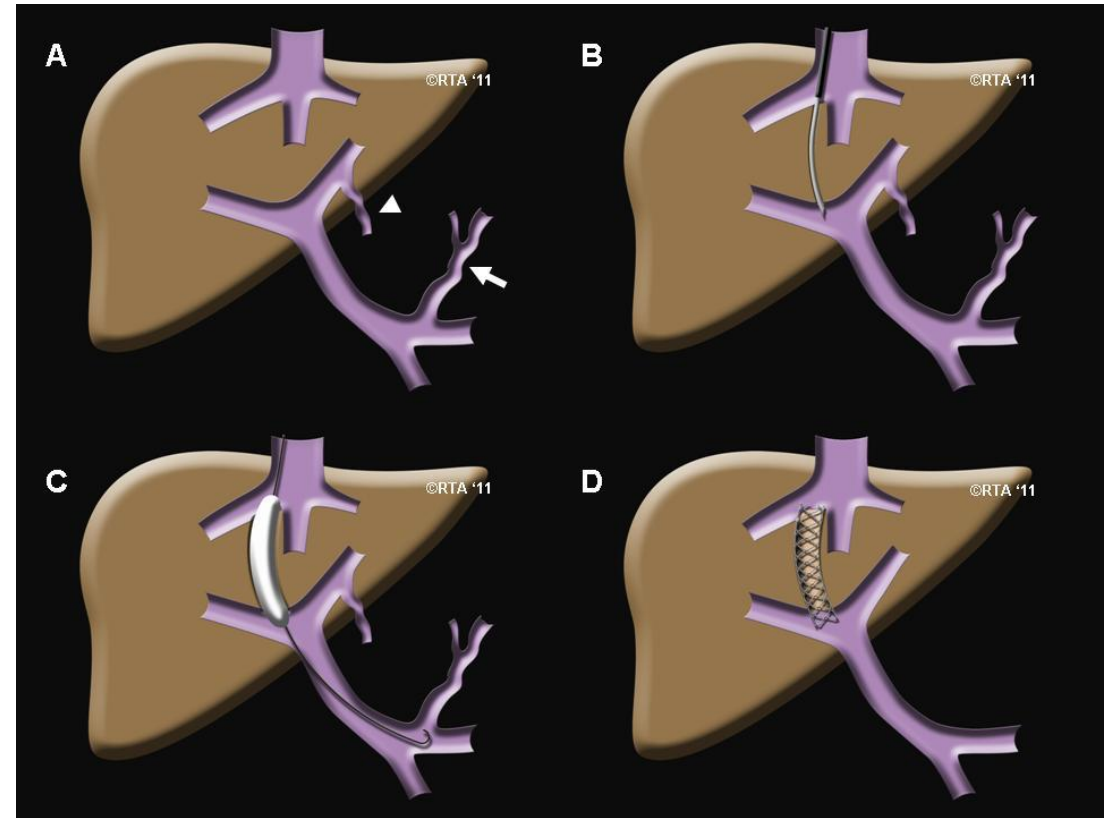


# H-graft Shunts – Small Diameter

- Indications similar for DSRS – can use ringed or un-ringed PTFE graft
  - Graft sizes of 8 or 10mm diameter
  - Can place in a porto-caval or splenorenal configuration
- Good reduction in portal pressure, no recurrence of bleeding, high patency rate
  - Minimal changes in rates of encephalopathy compared to pre-procedure
- Conduit easily removeable or closeable at time of transplant

# Transjugular Intrahepatic Portosystemic Shunts (TIPS)

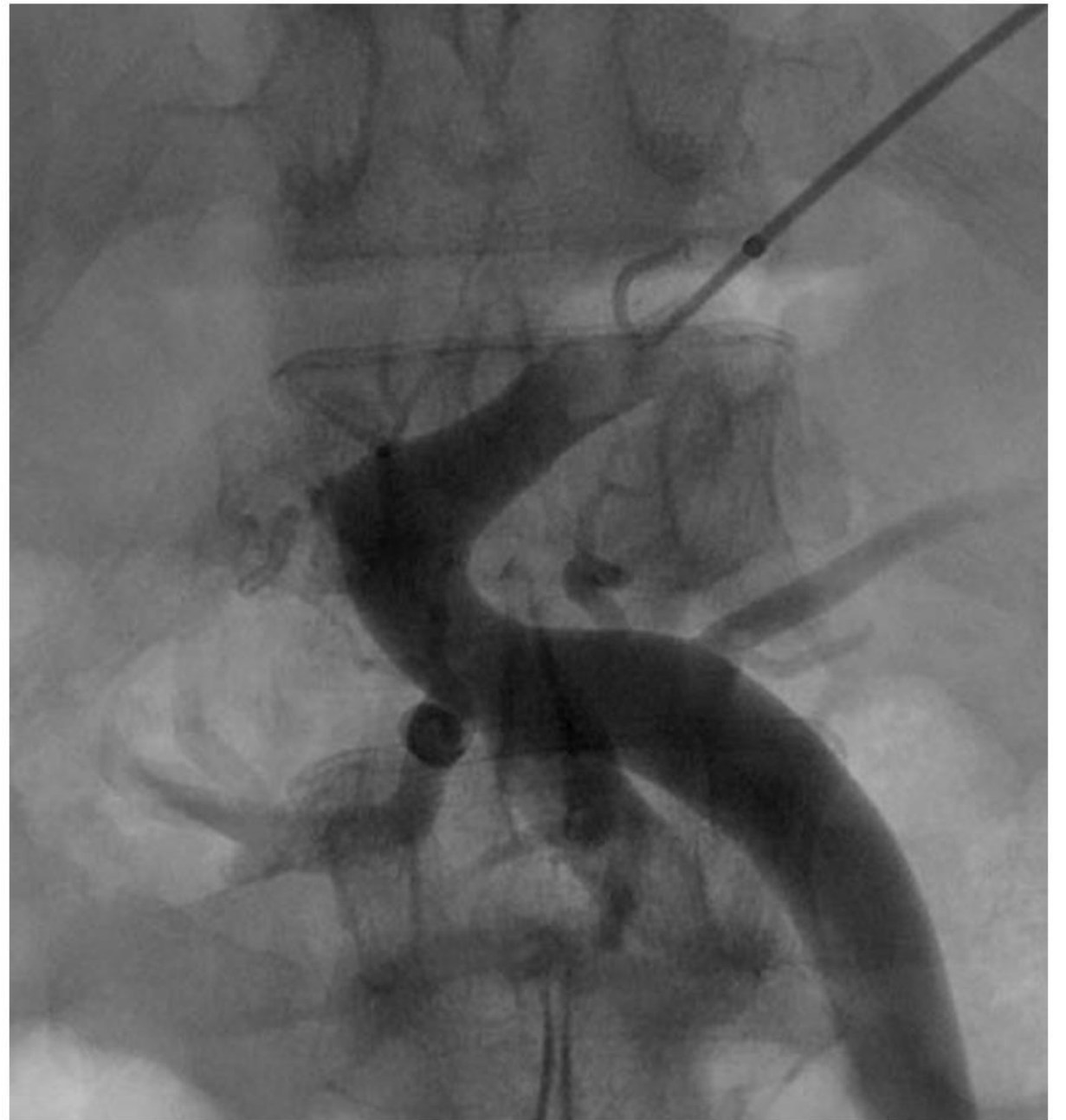- IR created shunt, usually from RHV to RPV
- Worsens encephalopathy
- Goal gradient <12mmHg
- Not 1st line Tx for bleeding

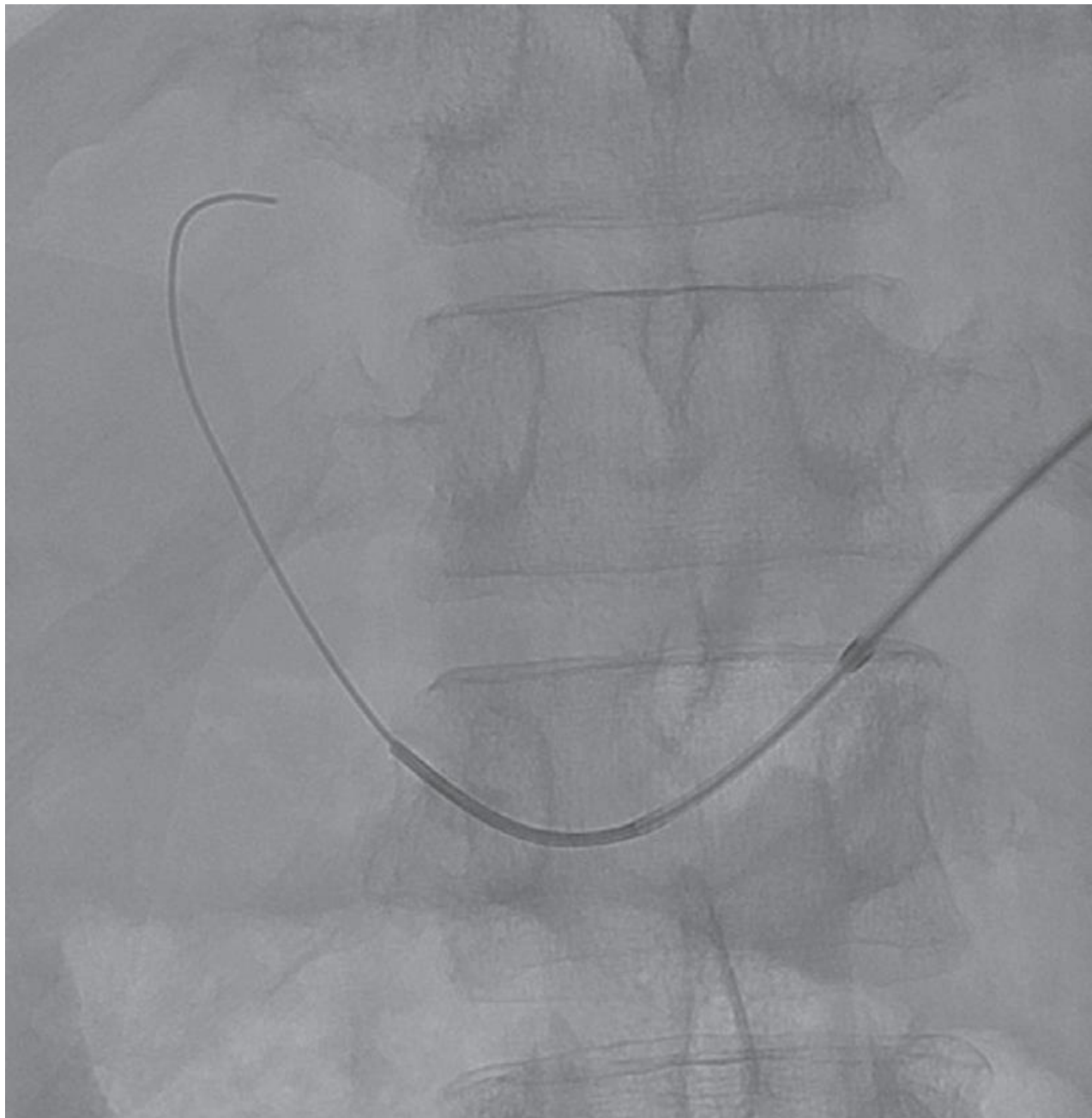

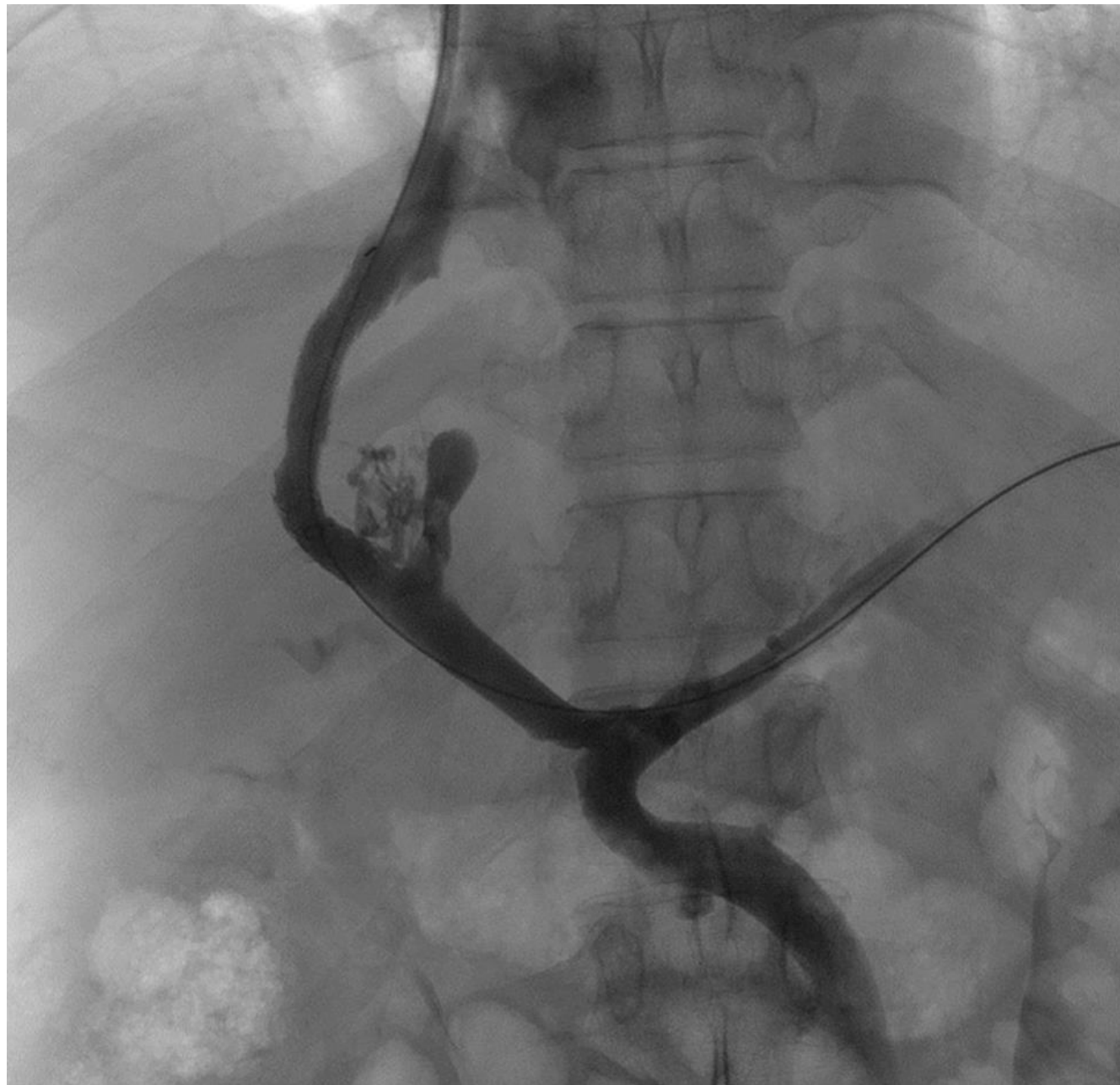# TIPS Indications/Contraindications

- Uncontrollable variceal hemorrhage / No endoscopic control
  - Prophylaxis against recurrent variceal bleed
  - Portal hypertensive gastropathy or enteropathy
  - Refractory ascites / Hepatic hydrothorax
  - **Portal vein thrombosis**
  - Budd-Chiari syndrome
  - Hepatorenal syndrome
  - Decompression before abdominal surgical procedures
- Absolute tips contraindications
    - Congestive heart failure / Severe tricuspid regurgitation
    - Severe pulmonary hypertension Uncontrolled infection or biliary obstruction
  - Relative tips contraindications
    - Obstruction of all hepatic veins
    - **Complete portal vein thrombosis**
      - Hepatocellular carcinoma (especially if centrally located)
    - Severe coagulopathy (INR greater than 5)
    - Thrombocytopenia (platelet count less than 20,000/cm<sup>3</sup>)
    - Moderate pulmonary hypertension
    - Recurrent or persistent severe spontaneous hepatic encephalopathy
      - Advanced liver failure (bili > 5 mg/dL or MELD > 17)
    - Cardiac dysfunction (ejection fraction less than 60%), cardiac diastolic dysfunction
    - Advanced age (>69 years old)
    - Extensive polycystic liver disease

# Portal Vein Recanalization







# Liver Transplantation – The Gold Standard

- OLT should immediately decompress the entire portal system
- Continued portal htn -> technical problem
  - Outflow obstruction
  - Portal vein stenosis
- Bleeding varices should be resolved
  - Sinestral hypertension
  - Banding site Ulceration

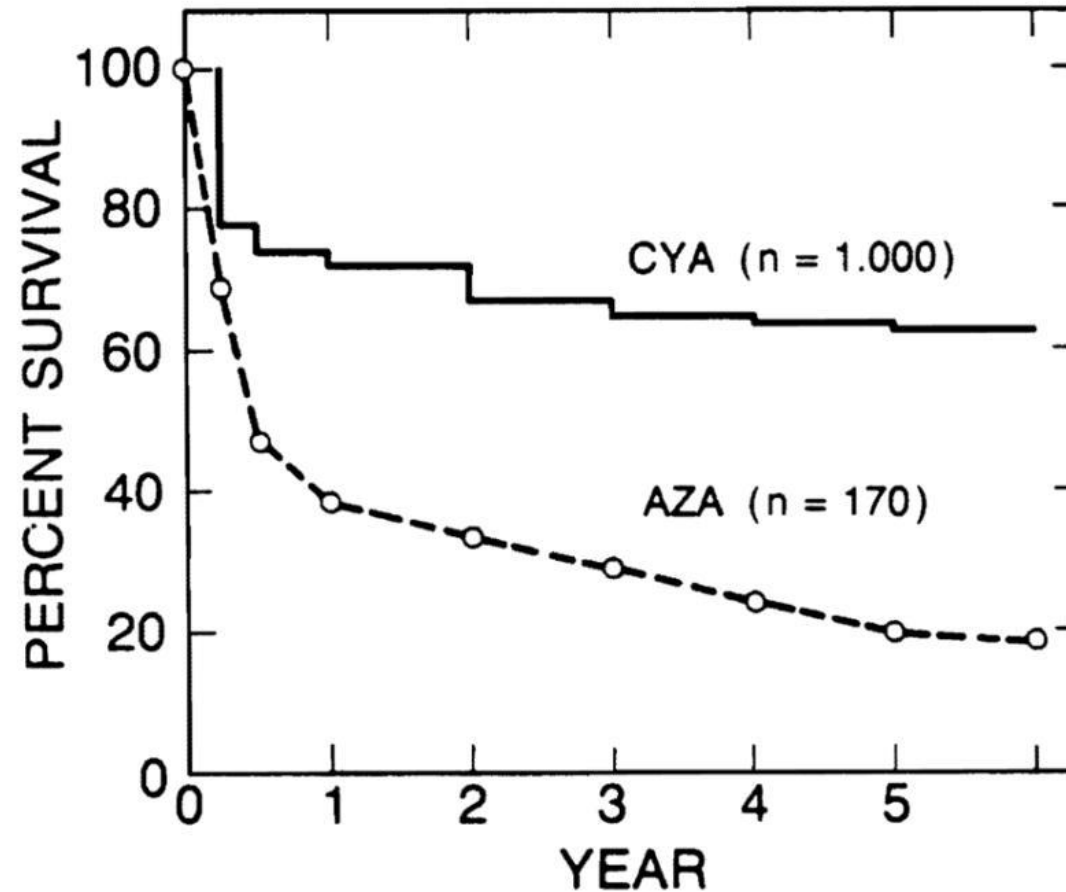


# Liver transplantation in the treatment of bleeding esophageal varices

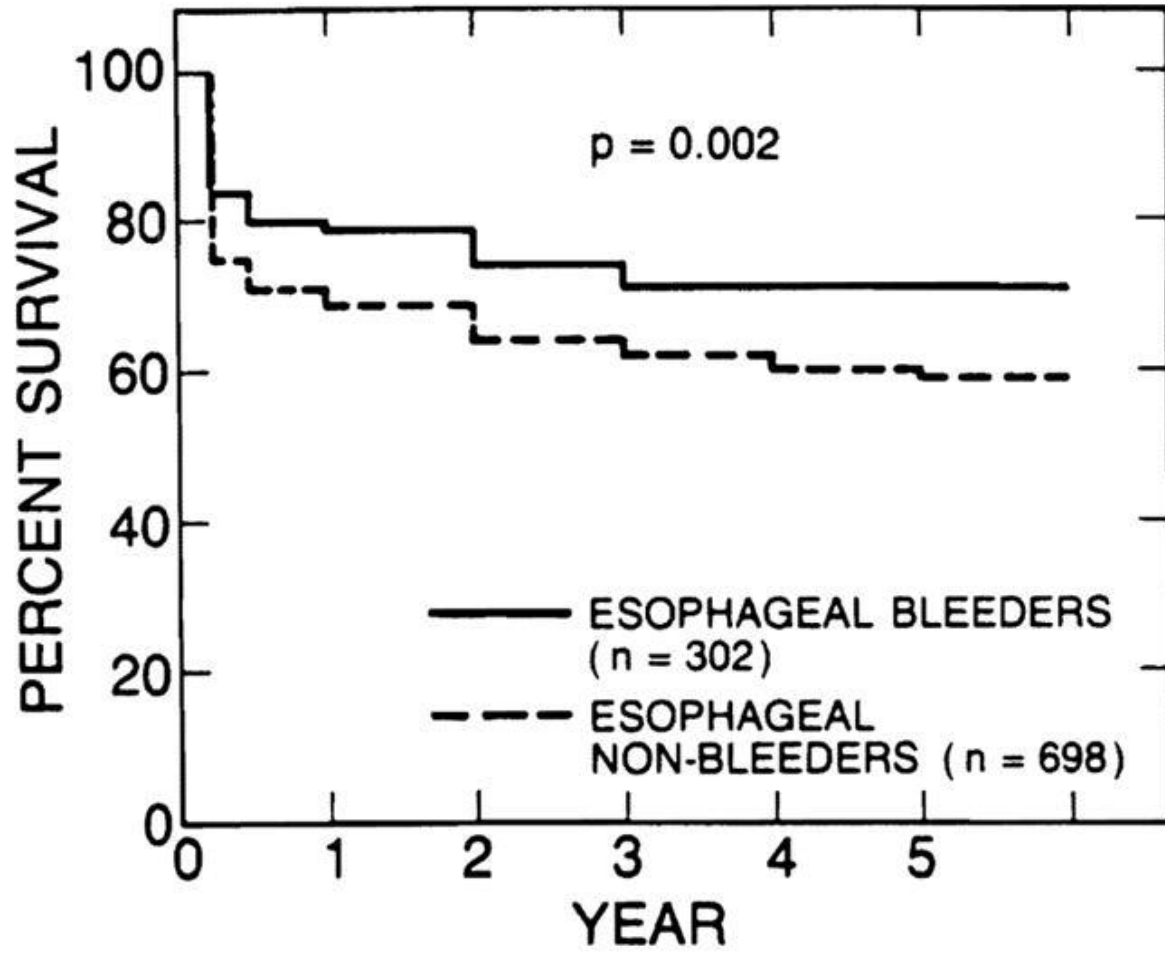
[Shunzaburo Iwatsuki](#)<sup>1</sup>, [Thomas E Starzl](#)<sup>1</sup>, [Satoru Todo](#)<sup>1</sup>, [Robert D Gordon](#)<sup>1</sup>, [Andreas G Tzakis](#)<sup>1</sup>, [J Wallis Marsh](#)<sup>1</sup>,  
[Leonard Makowka](#)<sup>1</sup>, [Baburao Koneru](#)<sup>1</sup>, [Andrei Stieber](#)<sup>1</sup>, [Goran Klintmalm](#)<sup>1</sup>, [Bo Husberg](#)<sup>1</sup>, [David van Thiel](#)<sup>1</sup>

► Author information ► Copyright and License information

PMCID: PMC2974305 NIHMSID: NIHMS242924 PMID: [3051474](#)







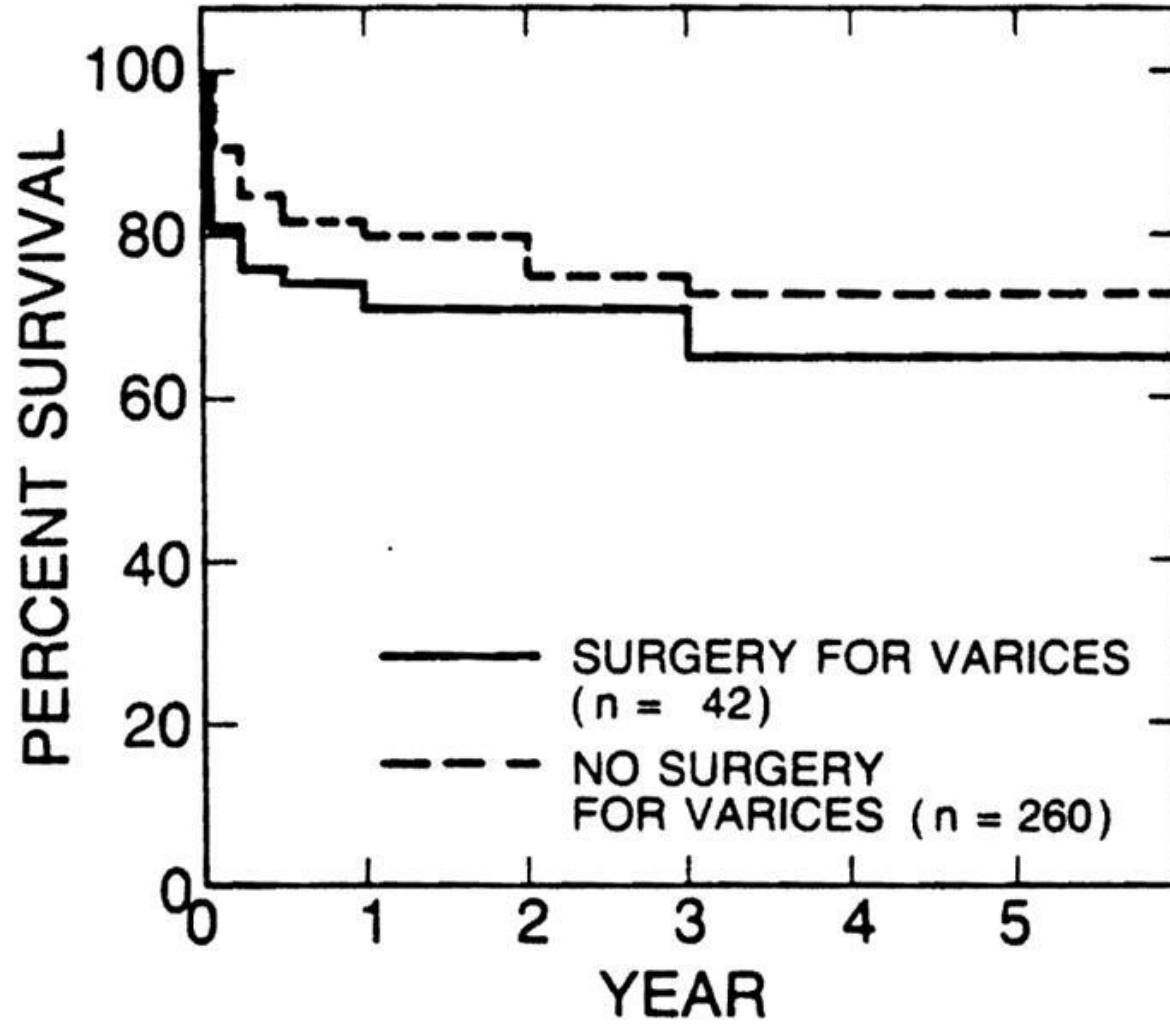


Table VI.

Survival comparison among various treatments for bleeding esophageal varices (Child's class C, poor liver function)

Treatment	No. of patients	Survival rates (%)				
		1 yr	2 yr	3 yr	4 yr	5 yr
<a href="#">Turcotte et al. (1973)</a>						
Nonselective shunt	50	36	32	22	20	17
<a href="#">Yamamoto et al. (1976)</a>						
Nonshunt operation	13	39	30	22	22	18
<a href="#">Warren et al. (1982)</a>						
Selective shunt	?	60*	53*	45*	40*	35*
Nonselective shunt	?	50*	40*	37*	20*	15*
<a href="#">Rikkers et al. (1984)</a>						
Shunt and nonshunt operation <sup>†</sup>	24	45	35*	30*	20*	17*
<a href="#">Chandler et al. (1985)</a>						
Shunt <sup>‡</sup>	30	36	30	25	20	13
<a href="#">Spence et al. (1985)</a>						
Nonshunt operation	25	70	53	38	38	35
Present study (1988)						
Liver transplantation	302	79	74	71	71	71

# Barrier for LT management of portal HTN

## Referral for liver transplant following acute variceal bleeding: a multicenter cohort study

Sofia Bragança<sup>a,\*</sup>, Marta Ramos<sup>b,\*</sup>, Sara Lopes<sup>c,\*</sup>, Gonçalo Alexandrino<sup>a</sup>, Milena Mendes<sup>b</sup>, Rui Perdigoto<sup>d</sup>, João Coimbra<sup>b</sup>, Hugo P. Marques<sup>d</sup> and Filipe S. Cardoso<sup>b,d</sup>

# References

- Tapper EB, Parikh ND. Diagnosis and Management of Cirrhosis and Its Complications: A Review. *JAMA* 2023; 329: 1589.
- Agarwal AK. Chapter 84 - Portal hypertensive bleeding: Operative devascularization [Internet]. In: Jarnagin WR, ed. *Blumgart's Surgery of the Liver, Biliary Tract and Pancreas, 2-Volume Set (Sixth Edition)*. Philadelphia: Elsevier, 2017
- Qi Y, Zhu S, Liu X et al. Endoscopic variceal ligation combined with Hassab's procedure in preventing the recurrence of esophageal varices. *Zhong Nan Da Xue Xue Bao. Yi Xue Ban = Journal of Central South University. Medical Sciences* 2007; 32: 368.
- Orozco H, Mercado MA, Chan C, Guillén-Navarro E, López-Martínez LM. A comparative study of the elective treatment of variceal hemorrhage with beta-blockers, transendoscopic sclerotherapy, and surgery: a prospective, controlled, and randomized trial during 10 years. *Annals of Surgery* 2000; 232: 216.
- Langer BF, Greig PD, Taylor BR. Emergency surgical treatment of variceal hemorrhage. *The Surgical Clinics of North America* 1990; 70: 307.
- Brand M, Prodehl L, Ede CJ. Surgical portosystemic shunts versus transjugular intrahepatic portosystemic shunt for variceal haemorrhage in people with cirrhosis. *The Cochrane Database of Systematic Reviews* 2018; 2018: CD001023.
- Orloff MJ, Isenberg JI, Wheeler HO et al. Randomized trial of emergency endoscopic sclerotherapy versus emergency portacaval shunt for acutely bleeding esophageal varices in cirrhosis. *Journal of the American College of Surgeons* 2009; 209: 25.
- Lillemoe KD, Cameron JL. The interposition mesocaval shunt. *The Surgical Clinics of North America* 1990; 70: 379.
- Khan S, Tudur Smith C, Williamson P, Sutton R. Portosystemic shunts versus endoscopic therapy for variceal rebleeding in patients with cirrhosis. *The Cochrane Database of Systematic Reviews* 2006; 2006: CD000553.
- Langer B, Taylor BR, Mackenzie DR, Gilas T, Stone RM, Blendis L. Further report of a prospective randomized trial comparing distal splenorenal shunt with end-to-side portacaval shunt. An analysis of encephalopathy, survival, and quality of life. *Gastroenterology* 1985; 88: 424.
- Hu H, Xu G, Li J, Yang S, Chai Z, Xu R. Small-diameter prosthetic H-graft portacaval shunts in the treatment of portal hypertension. *Chinese Medical Journal* 2004; 117: 195.
- Voskanian SÉ, Shabalin MV, Voevodin AL et al. H-shaped partial splenorenal shunting with the use of a reinforced graft made of porous polytetrafluoroethylene. *Angiologia I Sosudistaia Khirurgiia = Angiology and Vascular Surgery* 2020; 26: 103.
- Rajoriya N, Tripathi D. Historical overview and review of current day treatment in the management of acute variceal haemorrhage. *World Journal of Gastroenterology : WJG* 2014; 20: 6481.
- Iwatsuki S, Starzl TE, Todo S et al. Liver transplantation in the treatment of bleeding esophageal varices. *Surgery* 1988; 104: 697.

Thank you

